Pearls of Veterinary Practice

Laparoscopic-Assisted Gastropexy

Clarence A. Rawlings, DVM, PhD,
Diplomate ACVS

Introduction

Gastric dilatation-volvulus (GDV) is a life-threatening emergency in large dogs. The only universally accepted method to prevent GDV is a gastropexy. Other management practices are frequently recommended to reduce the likelihood of gastric dilatation, but a gastropexy is considered the only method to prevent volvulus. This paper describes the author's recently published technique for an incisional gastropexy with laparoscopic assistance.[1] The gastropexy is strong, and the technique is relatively quick and easy for the beginning laparoscopic surgeon to perform.

Gastric Dilatation-Volvulus

Full-term GDV usually occurs in deep-chested dogs having the typical history of eating a large meal, drinking a lot of water, and having postprandial excitement or stress. Signs include nonproductive attempts to vomit, drooling, pacing, rapid breathing, distended abdomen, and signs of shock. The combination of a large meal, excessive water intake, and aerophagia produces gastric distention. This gastric accumulation is exacerbated by delayed gastric emptying and decreased fluid absorption in the stomach. Gastric distention results in volvulus or rotation (clockwise rotation, as viewed from both a caudal and ventral view). Volvulus obstructs portal venous blood flow, which produces a combined cardiovascular and toxic shock. Decreased blood flow to the affected viscera produces vascular stasis, gastric ulcers, septic shock, and probably the release of myocardial depressant factors.[2,3]

Emergency treatment should be simultaneously directed toward relieving the gastric distention and treating the shock. After the initial emergency treatment, many patients are operated to examine the abdomen (i.e., stomach, spleen, and the remainder of the splanchnic organs), reposition the twisted stomach, and secure the gastric antrum to the right side of the abdomen.[2,3] Depending on organ viability, some dogs may require a partial gastrectomy or splenectomy.

Postoperative care is as crucial as the emergency anesthesia and surgery. Many cases require a few days of intensive care treatment and all require critical monitoring and treatment for the first 48 hours. Even with excellent surgical and medical care, the mortality of dogs with GDV is high. In a prospective series of 295 dogs operated for GDV, 15% died.[4] In contrast, only 1% of dogs with dilatation only, or with a nonconfirmed GDV, died.[4]

Indications and Surgical Options for a Prophylactic Gastropexy

Prevention of volvulus markedly increases the likelihood that a dog will not die during a bloat episode. The importance of a right-sided gastropexy

From the Department of Small Animal Medicine,
College of Veterinary Medicine,
University of Georgia,
Athens, Georgia 30602-7390.

for prevention of volvulus in dogs at risk for GDV has been well documented.[2,3] Dogs operated for GDV must have a permanent type of gastropexy to prevent recurrence. In a study of dogs treated medically for bloat, 68 survived the initial treatment and were followed for 1 year; 59 (81%) died within 1 year of the initial treatment.[5] In another series of cases, of 136 dogs operated for GDV, only 4.3% of the dogs treated with a gastropexy recurred, in contrast to 54.5% of the dogs that did not have a gastropexy during their initial surgery.[6] The dogs with a gastropexy had a median survival time of 547 days, as compared to 188 days for the dogs not treated with a gastropexy.[6] Several other authors have concluded that dogs treated with a prophylactic gastropexy are at a markedly reduced risk for volvulus.[3,5-8]

A prophylactic gastropexy should be performed in any dog with a history of bloat being managed medically. Other risk factors for an increased tendency to bloat have been identified in large epidemiological studies.[6,9-11] In a series of nearly 6,000 dogs, of which approximately one-third bloated, risk factors included increasing age, increasing weight, and a thoracic body confirmation with a large chest height/width ratio; purebred dogs were more likely to bloat than mixed-breed dogs, particularly the breeds of Great Dane, Weimaraner, St. Bernard, Gordon setter, and Irish setter.[9] The deep chest-to-width ratios and having a relative (particularly a parent) that had bloat were found to be high risk factors in a separate study.[11] Splenic torsion as treated by splenectomy has been followed by GDV in two dogs.[12] Although risk factors for GDV have been identified and the high mortality of GDV well documented, many susceptible dogs apparently do not receive gastropexies. One factor may be the common practice of an open laparotomy being done to perform a gastropexy. The laparoscopic-assisted technique described here is minimally invasive and produces essentially no complications after surgery.[1]

Several gastropexy techniques have been developed for use during a laparotomy. These include incisional gastropexy, circumcostal gastropexy, belt-loop gastropexy, and tube gastropexy placed either during an open laparotomy or percutaneously using a gastroscope.[2,3] The technique first developed was a tube gastropexy, which can be quickly done during laparotomy GDV treatment.[13] Because the tube gastropexy breaking strength is relatively low and potential complications include septic peritonitis, other gastropexy techniques were developed.[3,14-17] The goals for these gastropexy techniques are that they are simple to perform, produce a permanent attachment between the antrum and the right abdominal wall, do not alter gastric function, and have minimal complications.[7] A permanent adhesion requires that the mesothelium of the serosa and peritoneum be either removed, cauterized, or incised at the interface of the stomach and body wall.[2,17,18] The circumcostal technique is very strong, based on breaking-strength studies, and it results in a low GDV recurrence rate.[19-21] Infrequent complications include iatrogenic perforation of the seromuscular site,[21] pneumothorax, and rib fractures.[22] Other strong gastropexy techniques include the belt-loop and incisional techniques.[7,23,24]

Laparoscopic gastropexies have been developed.[25-27] These are done using suturing or stapling techniques performed within the abdomen using laparoscopic techniques. Three trocars and a high degree of laparoscopic surgical skill are required. The laparoscopic-assisted technique described herein only uses the laparoscope to identify and grasp the antrum. Once the antrum is exteriorized, the gastric incision and gastropexy can be simply done by an open technique.

Technique Development and Initial Clinical Experiences

Eight research dogs were used to develop this incisional gastropexy technique.[1] The dogs were monitored for 1 month postoperatively, at which time they were evaluated by gastrograms, ultrasonography of the gastropexy sites,[28] necropsy with histopathology, and breaking-strength testing of the gastropexy. All dogs had normal gastric function after surgery and minimal adverse responses to surgery as evidenced clinically by all dogs eating normally and having normal bowel movements within the first few days after surgery as well as none exhibiting vomiting. Additionally, none of the dogs exhibited fever, abnormal behavior, or had evidence of a significant stress leukogram. Using ultrasonography, the adhesion site could be identified as the site where the stomach was adhered to the abdominal wall. The mean length of the adhesion site was 2.9 cm, and the average tensil strength (i.e., breaking strength) of the gastropexy was 106.5 Newton.[1] The adhesion had mature and abundant fibroplasia, indicating a strong scar. These gastropexy results indicate that this laparoscopic-assisted technique produces a strong adhesion similar to the strongest gastropexy previously reported. This technique has been applied to client-owned dogs. The dogs have had minimal postoperative complications, and none developed gastrointestinal problems.[1]

Technique for Laparoscopic-Assisted Gastropexy[1]

Laparoscopy should be performed during general anesthesia and positive-pressure ventilation. Dogs are placed in dorsal recumbency. A trocar cannula for the viewing telescope is placed on the ventral midline 2- to 3-cm caudal to the umbilicus [Figure 1]. After distending the peritoneal cavity with carbon dioxide, a 0°, 5- or 10-mm laparoscope[a] is placed through the cannula. The laparoscope is connected to a video camera[b] and a xenon light source.[c] The second trocar cannula is placed lateral to the right margin of the rectus abdominus and 3-cm caudal to the last rib [Figure 1]. A 10-mm laparoscopic Babcock forcep[d] is passed through the right paramedian port to manipulate the cranial abdominal organs and then to grasp the antrum of the stomach. The antral site for grasping with the forceps and for the incisional gastropexy is midway between the mesenteric and antimesenteric sides, approximately 5- to 7-cm orally from the pylorus.

The Babcock forceps and antrum are exteriorized by removing the right side cannula and extending the cannula's

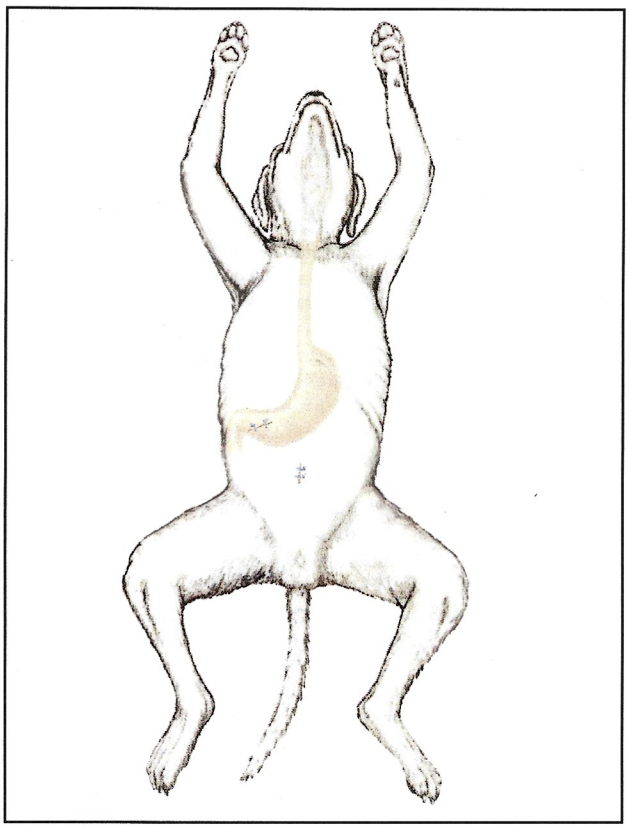

Figure 1—Overview of the laparoscopic-assisted incisional gastropexy. There are two abdominal incisions, midline for the laparoscope and right side for the gastropexy.

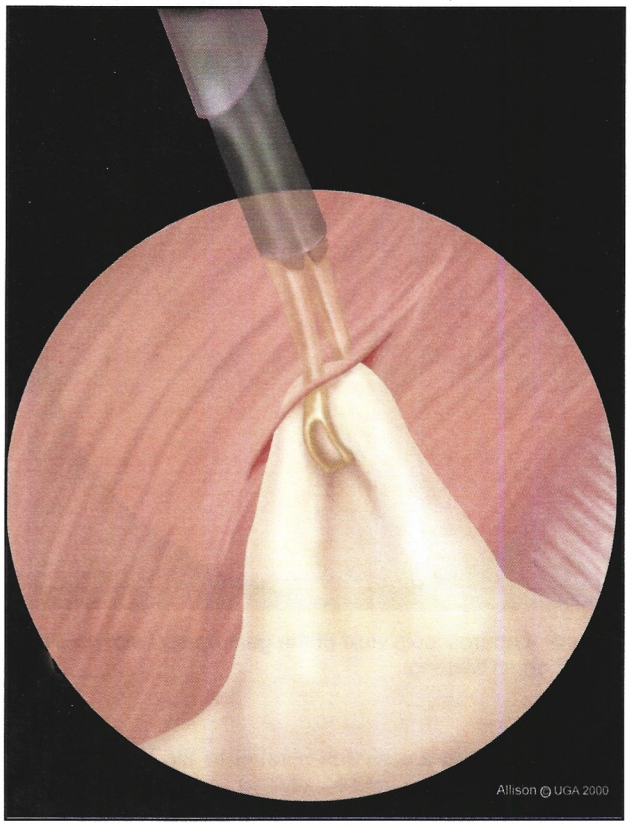

Figure 2—The antrum is grasped midway between the greater and lesser curvatures, approximately 5 to 7 cm orally from the pylorus. The laparoscopic Babcock forceps are placed perpendicular to the long axis of the stomach. The Babcock forceps, the right-sided trocar cannula, and the antrum are brought through the lengthened cannula's incision.

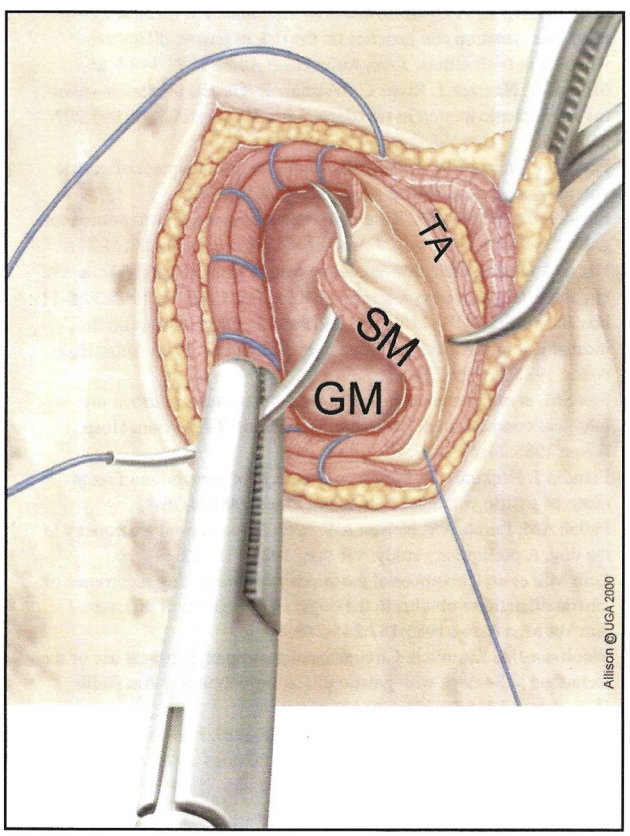

Figure 3—Cruciate retraction sutures are placed approximately 4-cm apart at the ends of a planned seromuscular incision. The seromusuclar layer is incised (3.5 to 4 cm) down to the gastric mucosa, and a dissection plane developed between these two layers in both directions from the initial incision. The seromuscular layer is sutured to the peritoneum and transversus abdominus. SM=seromuscular layer of the stomach; GM=gastric mucosa; TA=transversus abdominus muscle. (From Rawlings CA, Foutz TL, Mahaffey MB, Howerth EW, Bement S, Canalis C. A rapid and strong laparoscopic-assisted gastropexy in dogs. Am J Vet Res 2001;62[6]:871-875. Reprinted with permission.)

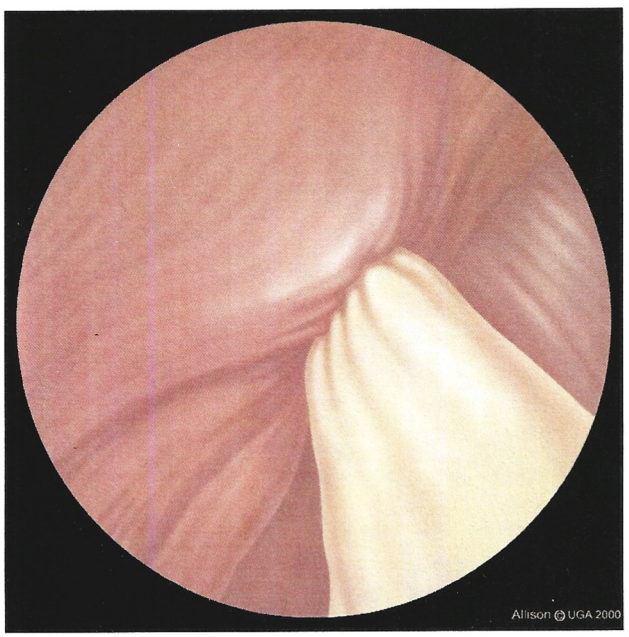

Figure 4—Laparoscopic view of the gastropexy, with no evidence of antral twisting.

incision to 4 cm in a direction parallel to the last rib. The antral exteriorization should be viewed via the laparoscope in order to avoid twisting of the antrum [Figure 2]. Traction sutures with a *0* synthetic, monofilament suture are placed in a cruciate fashion, orally and at least 4-cm aborally, at the commissures of the intended gastropexy. An incision at least 4-cm long is made through the serosa and muscular layer of the antrum. The sides of the incision should be dissected from the mucosa to insure that the sutures are not placed through the mucosa and that adequate muscle tissue is exposed for the gastropexy. A simple continuous pattern of *2-0* or *0* synthetic, monofilament, absorbable suture is placed to appose the seromuscular layer of the antrum to the transversus abdominus muscle [Figure 3]. Separate closure sutures are placed on the cranial and caudal sides of the incisions. The oblique abdominal muscles are closed with interrupted synthetic sutures, and the remainder of the incision is closed according to the surgeon's preference. After viewing the gastropexy for position and orientation [Figure 4], the midline cannulae are removed and the incision is closed.

A more complete procedure description has been published. For veterinarians wishing to acquire laparoscopic skills and equipment, they are encouraged to review a recently published textbook[29] and to participate in "hands-on" laboratory courses.

[a] Olympus 0° 10-mm, 29-cm telescope; Olympus, Tuttlinger, Germany
[b] Tricam camera and image processor; Karl Storz Endoscopy American, Culver City, CA
[c] Zenon nova; Karl Storz Endoscopy American, Culver City, CA
[d] Babcock forceps; Ethicon-Endo, Cincinnati, OH

Acknowledgment

The authors would like to thank Ms. Allison Wright who prepared the illustrations of the surgical procedure.

References

1. Rawlings CA, Foutz TL, Mahaffey MB, *et al.* A rapid and strong laparoscopic-assisted gastropexy in dogs. Am J Vet Res 2001;62:871-875.
2. Ellison GW. Gastric dilatation volvulus: surgical prevention. Vet Clin North Am Sm Anim Pract 1993;23:513-530.
3. Hosgood G. Gastric dilatation-volvulus in dogs. J Am Vet Med Assoc 1994;204:1742-1746.
4. Brockman JD, Washabau RJ, Drobatz KJ. Canine gastric dilatation-volvulus syndrome in a veterinary critical care unit: 295 cases (1986-1992). J Am Vet Med Assoc 1995:207-460.
5. Eggertsdottir AV, Moe L. A retrospective study of conservative treatment of gastric dilatation-volvulus in the dog. Acta Vet Scand 1995;36:175-184.
6. Glickman LT, Lantz GC, Schellenberg DB, Glickman NW. A prospective study of survival and recurrence following the acute gastric dilatation-volvulus syndrome in 136 dogs. J Am Anim Hosp Assoc 1998;34:253-259.
7. Whitney WO. Complications associated with the medical and surgical management of gastric dilatation-volvulus in the dog. Probl Vet Med 1989;1:268-280.
8. Whitney WO, Scavelli TD, Matthiesen DT, *et al.* Belt-loop gastropexy: technique and surgical results in 20 dogs. J Am Anim Hosp Assoc 1989;25:75-83.
9. Glickman LT, *et al.* Analysis of risk factors for gastric dilatation and dilatation-volvulus in dogs. J Am Vet Med Assoc 1994;204:1465-1471.
10. Glickman LT, Glickman NW, Schellenberg DB, *et al.* Multiple risk factors for the gastric dilatation-volvulus syndrome in dogs: a practitioner/owner case-control study. J Am Anim Hosp Assoc 1997;33:197-204.
11. Schellenberg D, Yi Q, Glickman NW, Glickman LT. Influence of thoracic conformation and genetics on the risk of gastric dilatation-volvulus in Irish setters. J Am Anim Hosp Assoc 1998;34:64-66.
12. Millis DL, Nemzek J, Riggs C, Walshaw R. Gastric dilatation-volvulus after splenic torsion in two dogs. J Am Vet Med Assoc 1995;207:314-315.
13. Parks JL, Greene RW. Tube gastrostomy for the treatment of gastric volvulus. J Am Anim Hosp Assoc 1976;12:168-172.
14. Flanders JA, Harvey HJ. Results of tube gastrostomy as treatment for gastric volvulus in the dog. J Am Vet Med Assoc 1984;185:74-77.
15. Fox SM. Gastric dilatation-volvulus: results from 31 surgical cases of circumcostal gastropexy vs. tube gastrostomy. Calif Vet 1985;39:8-11.
16. Fox SM, Ellison GW, Miller GJ, Howells D. Observations on the mechanical failure of three gastropexy techniques. J Am Anim Hosp Assoc 1985;21:729-734.
17. Fox SM, *et al.* Circumcostal gastropexy versus tube gastrostomy: histological comparison of gastropexy adhesions. J Am Anim Hosp Assoc 1988;24:273-279.
18. Frendin J, Funkquist B. Fundic gastropexy for prevention of recurrence of gastric volvulus. J Sm Anim Pract 1990;31:78-82.
19. Fallah AM, Lumb WV, Nelson AW, *et al.* Circumcostal gastropexy in the dog. A preliminary study. Vet Surg 1982;11:9-12.
20. Leib MS, *et al.* Circumcostal gastropexy for preventing recurrence of gastric dilatation-volvulus in the dogs: an evaluation of 30 cases. J Am Vet Med Assoc 1985;187:245-248.
21. Woolfson JM, Kostolich. Circumcostal gastropexy: clinical use of the technique in 34 dogs with gastric dilatation-volvulus. J Am Anim Hosp Assoc 1986;22:825-830.
22. Whitney WO, Scavelli TD, Matthiesen DT, *et al.* Belt-loop gastropexy: technique and surgical results in 20 dogs. J Am Anim Hosp Assoc 1989;25:75-83.

23. Schulman AJ, Lusk R, Lippincott CL, *et al.* Muscular flap gastropexy: a new surgical technique to prevent recurrences of gastric dilatation-volvulus syndrome. J Am Anim Hosp Assoc 1986;22:339-346.
24. MacCoy DM, Sykes GP, Hoffer RE, Haarvey HJ. A gastropexy technique for permanent fixation of the pyloric antrum. J Am Anim Hosp Assoc 1982;18:763-768.
25. Thompson SE, *et al.* Laparoscopic stapled incisional gastropexy. Proceedings, ACVS Veterinary Symposium, Miami, Florida 1992 (abstract).
26. Wilson ER, Henderson RA, Montgomery RD, Kincaid SA, Wright JC, Hanson RR. A comparison of laparoscopic and belt-loop gastropexy in dogs. Vet Surg 1996;25:221-227.
27. Hardie RJ, Flanders JA, Schmidt P, Credille KM, Pedrick TP, Short CE. Biomechanical and histological evaluation of a laparoscopic stapled gastropexy technique in dogs. Vet Surg 1996;25:127-133.
28. Wacker CA, Weber UT, Tanno F, Lang J. Ultrasonographic evaluation of adhesions induced by incisional gastropexy in 16 dogs. J Sm Anim Pract 1998;39:379-384.
29. Freeman LJ. Veterinary endosurgery. St. Louis: Mosby, 1998:44-60.